CASE REPORT

AN UNUSUAL MANNER OF DEATH IN A CASE OF ELECTROCUTION: AN AUTOPSY CASE REPORT

Suraj Sundaragiri[1], Rudra Vijay[2], Chaitanya Mittal[3]
[1&2] Department of Forensic Medicine and Toxicology, Gandhi Medical College, Secunderabad, Telangana, India[3] Forensic Medicine & Toxicology AIIMS Patna Phulwari sharif, Patna, Bihar, India

Corresponding Author
Dr. Sundaragiri Suraj | Email: drsurajfm@gmail.com | Mobile: 9908267327
Received: May 11, 2024; Accepted: January 11, 2025

ABSTRACT

Suicidal deaths by electrocution are rare and pose a diagnostic challenge for forensic pathologists. We present an unusual case of suicidal electrocution in a 20-year-old male construction worker who used bare copper wiring twisted around his hands. The post-mortem examination revealed multiple electrical entry (Joule burn) injuries on both hands and multiple exit wounds on the back.
Keywords: Electrocution, suicide, Joule burns, exit wounds, autopsy

INTRODUCTION

Electrocution deaths from domestic electrical supply (240V) are typically accidental in nature.[1] Suicidal and homicidal electrocution deaths are rare.[2] According to Indian national data, only 0.4% of suicides are attributed to electrocution.[3] Suicidal electrocution is more often observed among individuals with psychiatric illnesses, particularly depressive disorders.[4] In suspected electrocution fatalities, the manner of death is frequently a diagnosis of exclusion due to inconclusive findings, making detailed scene investigation and autopsy crucial.[5] This case report highlights a rare suicidal electrocution involving a construction worker.

Case Report

A 20-year-old male mason was found unconscious at a construction site of a hospital building. He was taken to the hospital by co-workers and declared brought dead by the casualty medical officer. The body was subsequently transferred to the mortuary, and a medicolegal autopsy was requested.

Investigation revealed that the deceased had accessed a nearby 240V electrical outlet lacking a circuit breaker. He had manually stripped the insulation from the wires and wrapped the bare copper conductors around his hands. Co-workers discovered him unresponsive and disconnected the power supply before removing the wires and transporting him to the hospital. The exact duration of current exposure was unknown.

Autopsy examination revealed multiple healed hesitation cuts on the anterior aspect of the left forearm. Bare copper wire was still wrapped around the fingers of the left hand at the time of autopsy [Figure 1]. Multiple Joule burn injuries—characteristic entry wounds—were noted on the thumb, index, and middle fingers of the left hand [Figure 2], and similar burns were observed on the index and middle fingers of the right hand [Figure 3]. Exit wounds were present over the right scapular and right gluteal regions [Figure 4].

The entry wounds displayed classic features: circumferential electric burns with raised, charred margins, pale central zones, and peripheral erythema. Exit wounds presented as skin splits with raised, charred margins and yellowish discoloration at the base. No gross pathological abnormalities were observed in the heart. Visceral organs were congested. Toxicological screening was negative. The cause of death was attributed to electrical injuries.

Discussion

In our hospital mortuary, the most common methods of suicide are hanging and poisoning.

Suicidal deaths due to electrocution, especially in non-electricians, are rare.[6,7] Most reported cases of suicidal electrocution involve individuals with electrical expertise. The victim in this case, however, was a mason, making the incident especially uncommon.

Electrocution often leaves distinguishable external injuries. Entry wounds, or Joule burns, typically appear as dry, charred lesions with raised margins, often surrounded by a zone of pallor and erythema. Exit wounds, though less distinct, may appear as lacerations or splits with irregular borders and underlying

Figure1: Electric wires over the body.

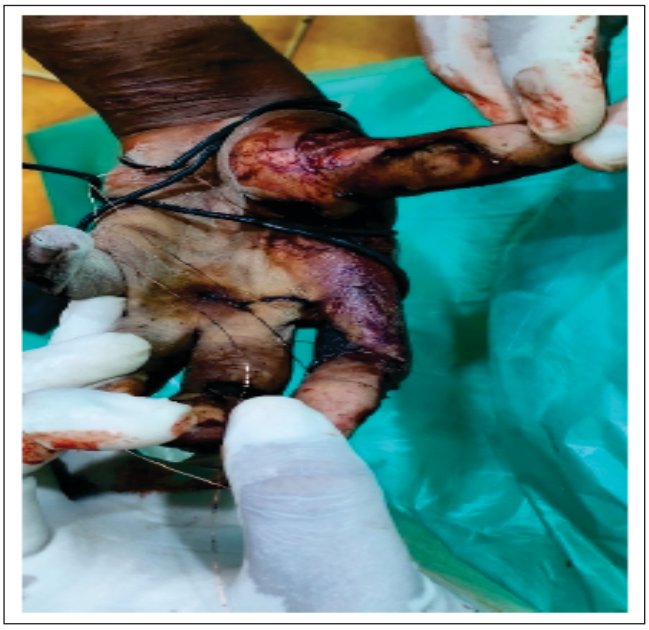

Figure 2: Bare copper wirings on the left hand with electric entry wounds.

Figure 3: Electric entry wounds onright hand

Figure 4: Exit wounds on right scapula(a) and gluteal region(b).

tissue charring. These features were clearly observed in this case.

It is important to note that electrocution injuries can sometimes be absent, especially when the body is wet or submerged in water, complicating diagnosis.[8] However, in this instance, the presence of both entry and exit wounds clearly mapped the current's path through the body.

Electrocution can cause death through several mechanisms: ventricular fibrillation, respiratory arrest, or direct injury to autonomic centers in the brainstem. [9] The deceased also showed evidence of prior suicidal behavior, as indicated by healed hesitation cuts on the forearm. The presence of bare wires wound around both hands further supports intentional self-harm.

Given the unusual manner and circumstances of this death, this case highlights the importance of workplace safety protocols, early detection of mental health issues, and the need for comprehensive suicide prevention strategies focused on psychiatric care.[10]

Conclusion

Determining the manner of death in electrocution cases remains a forensic challenge. However, meticulous autopsy findings and careful evaluation of circumstantial evidence can guide forensic pathologists in making a definitive conclusion. In this case, the presence of electrical wires, matching electrical injuries, and evidence of prior suicidal behavior supported the conclusion that the death was suicidal in nature due to electrocution. This case also emphasizes the necessity for improved mental health screening and safety awareness among construction workers.

References:

1. Sundaragiri S, Kumaran M S, Janarthanan V, Mittal C, GP Devnath. (February 07, 2024) Electro-Amputation of Lower Limbs Due to a High-Voltage Shock: Report of an Unusual Case. Cureus 16(2): e53808. doi:10.7759/cureus.53808
2. Wick R, Gilbert JD, Simpson E, Byard RW. Fatal electrocution in adults—a 30-year study. Medicine, science and the law. 2006 Apr;46(2):166-72.
3. Accidental deaths & suicides in India 2015. National Crime Records Bureau. Ministry of Home Affairs. Government of India. (2022). Accessed: July 14, 2023: https://ncrb.gov.in/uploads/files/AccidentalDeathsSuicidesinIndia2022v2.pdf
4. Kim DY, Lee S, Kim DJ. Review of suicidal electrocution in South Korea from 2008 year to 2018 year. Korean Journal of Legal Medicine. 2019 Nov 1;43(4):138-43.
5. Mesrati MA, Mahjoub Y, Boussaïd M, Limem H, Abdejlil N, Chadly A, Aissaoui A. Unusual cases of suicidal electrocution using a homemade device. Medico-Legal Journal. 2021 Jul 20:00258172211024836.
6. Byard RW, Hanson KA, Gilbert JD, James RA, Nadeau J, Blackbourne B, Krous HF. Death due to electrocution in childhood and early adolescence. Journal of paediatrics and child health. 2003 Jan;39(1):46-8.
7. Das S, Patra AP, Shaha KK, Sistla SC, Jena MK. High-voltage suicidal electrocution with multiple exit wounds. The American journal of forensic medicine and pathology. 2013 Mar 1;34(1):34-7.
8. Wick R, Byard RW. Electrocution and the autopsy. Forensic pathology reviews. 2008:53-66.
9. Wick R, Gilbert JD, Simpson E, Byard RW. Fatal electrocution in adults—a 30-year study. Medicine, science and the law. 2006 Apr;46(2):166-72.
10. Cavanagh JT, Carson AJ, Sharpe M, Lawrie SM. Psychological autopsy studies of suicide: a systematic review. Psychological medicine. 2003 Apr;33(3):395-405.